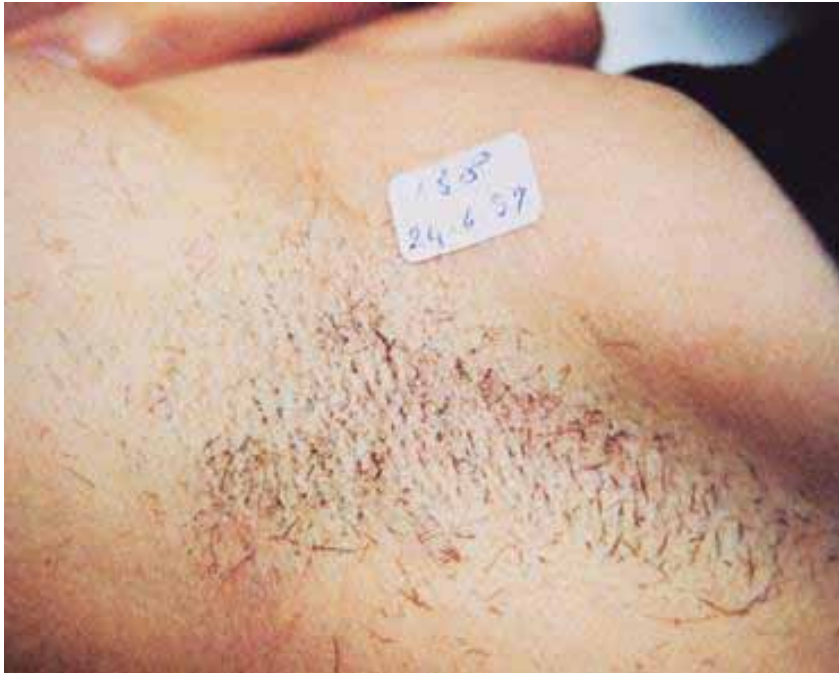
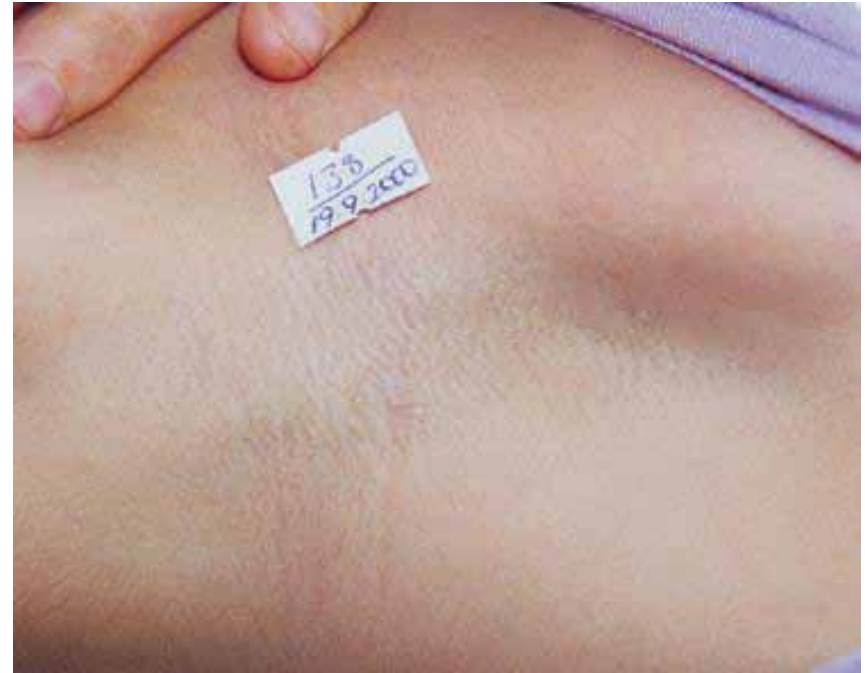
Clinical Results – Female Underarm



Pre Treatment

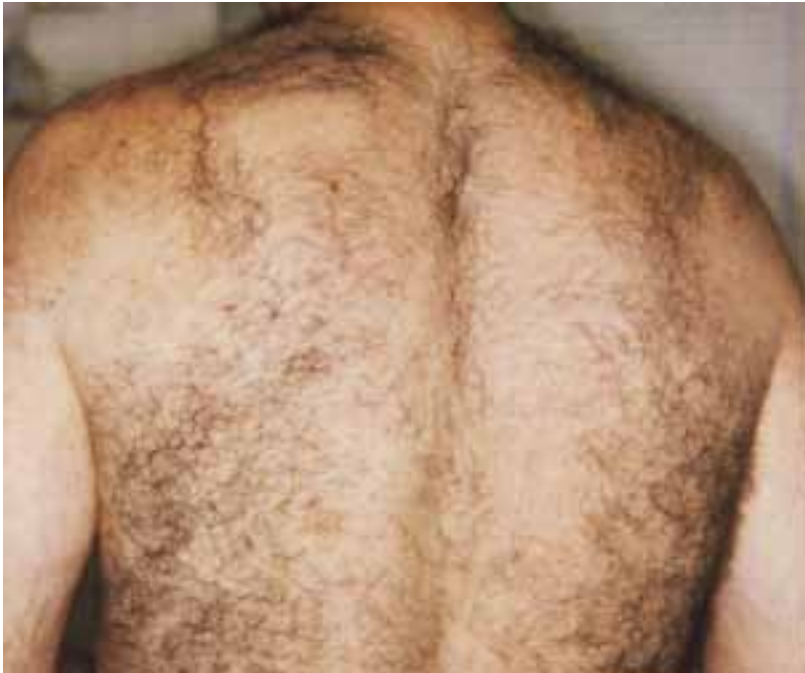

Post Treatment

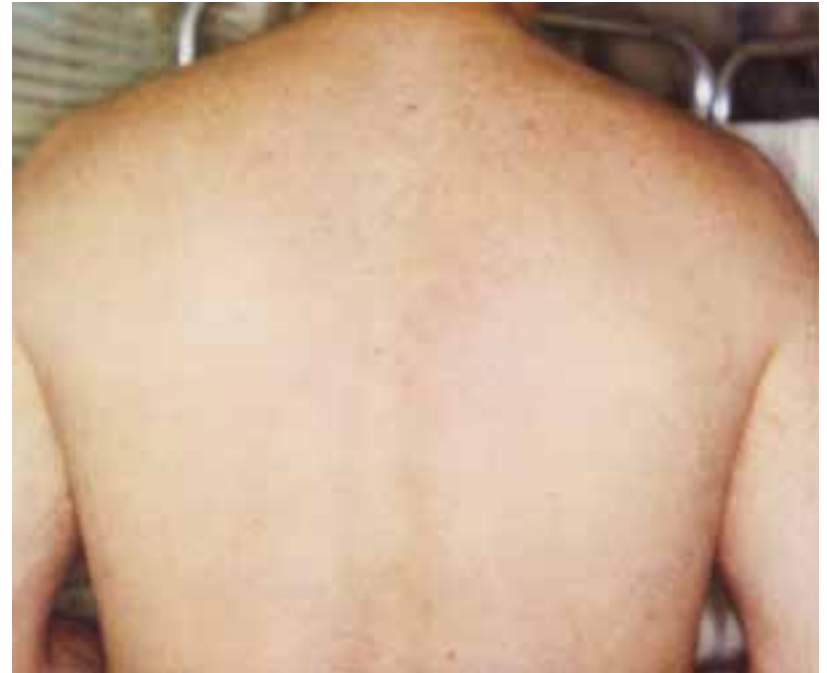15 mm, 25 J/cm², DCD: 30–60, 3 tx

Photos Courtesy of Münevver Ercan, M.D.

Clinical Results – Male Back



Pre Treatment

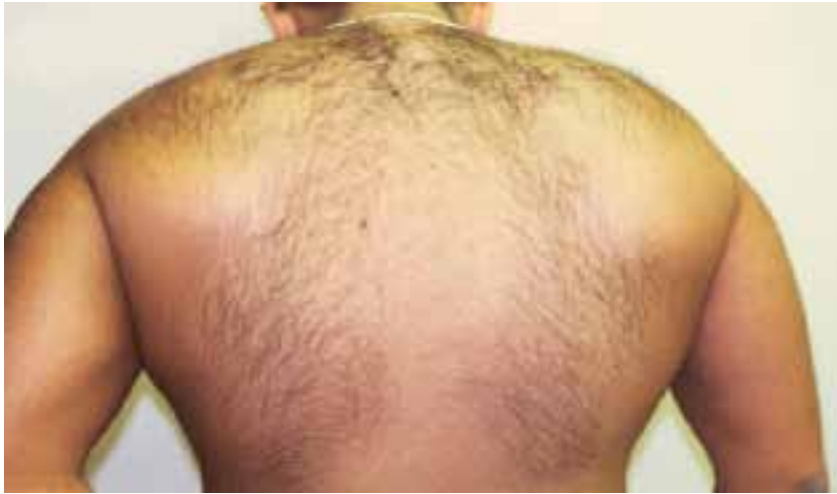

Post Treatment

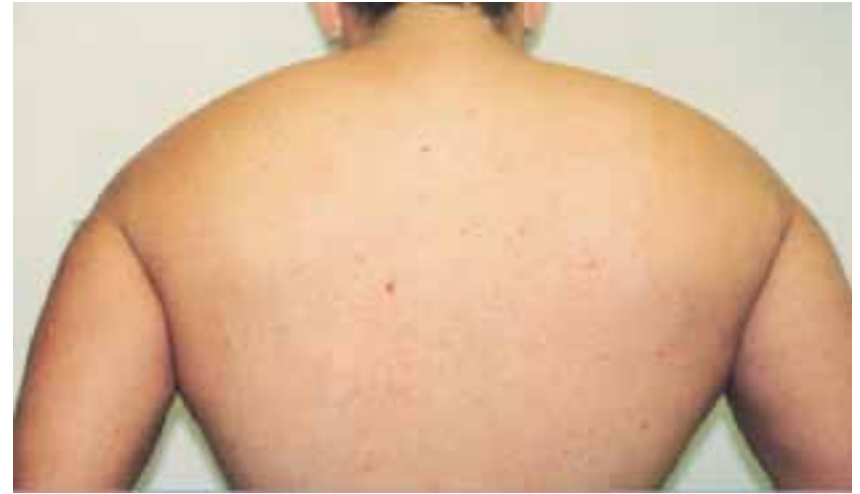15 mm, 14 J/cm², DCD: 80–50, 5tx

Photos Courtesy of Marcele C. Kutun, M.D.

Clinical Results – Male Back



Pre Treatment

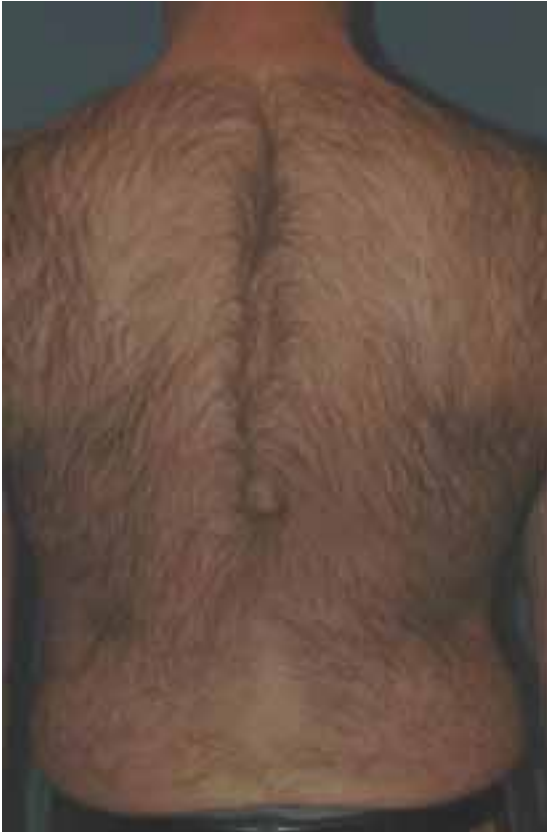

Post Treatment

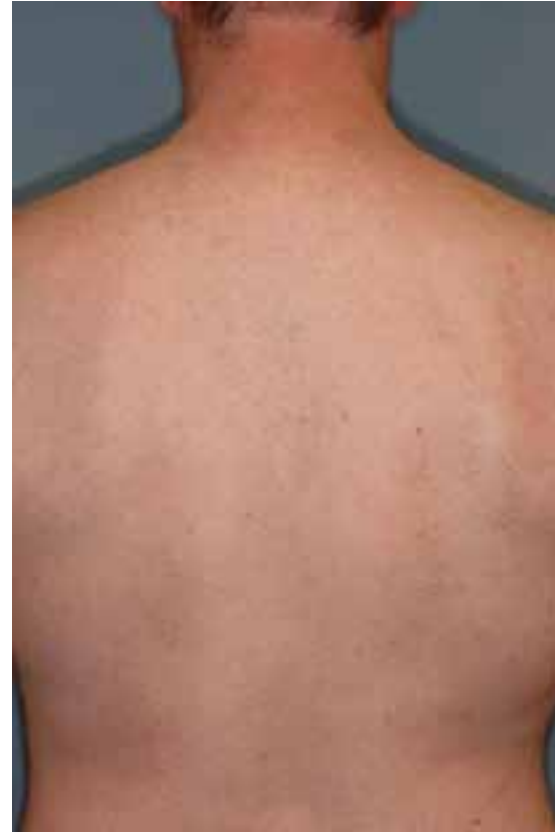12 mm, 16 J/cm², DCD: 80–80, 2tx

Photos Courtesy of Kathleen P. Hutton, M.D.

Clinical Results – Male Back



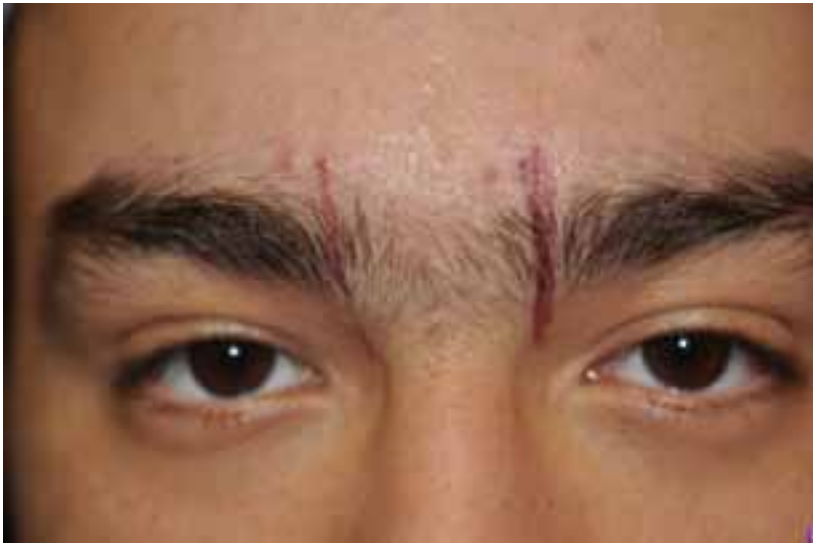Pre Treatment



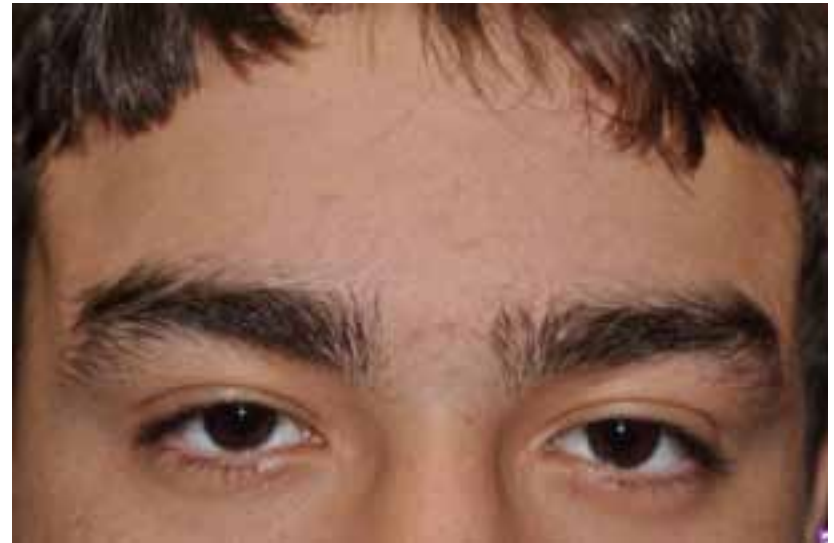3 Months Post 4 Treatments

Photos Courtesy of Jill Waibel, M.D.

Clinical Results – Male Eyebrows



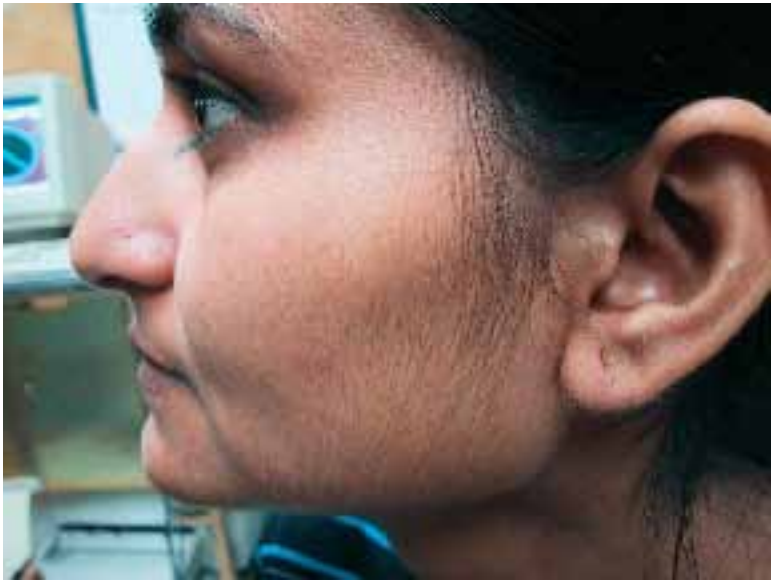Pre Treatment



3 Months Post Treatment

Photos Courtesy of Jill Waibel, M.D.

Clinical Results – Female Face



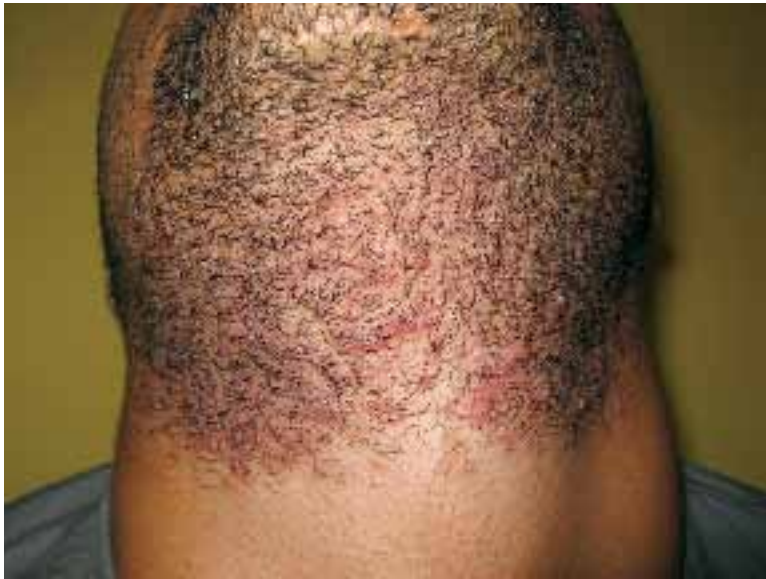Pre Treatment



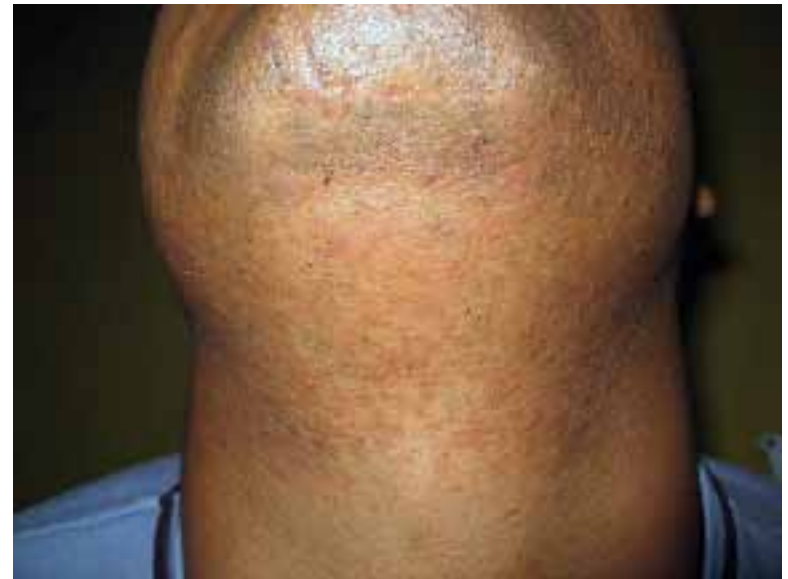Post Treatment

Photos Courtesy of F. Jenkins, RN

Clinical Results – Male Beard Bumps (neck/under chin)



Pre Treatment

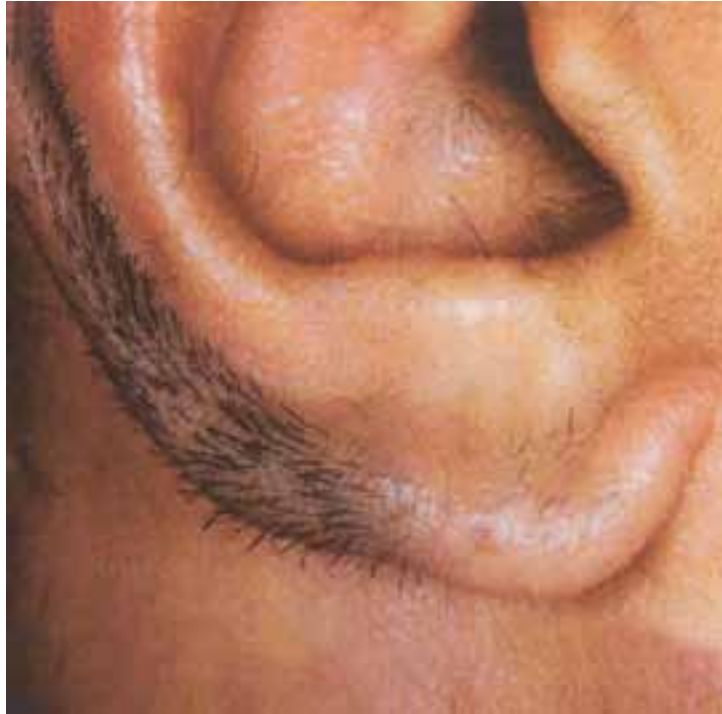


Post Treatment #5

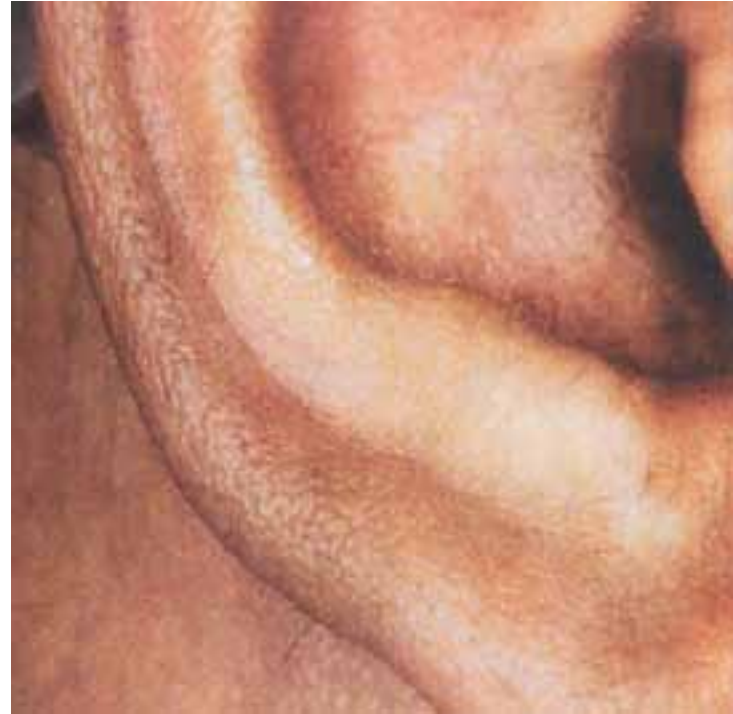
1064 nm, 12 mm, 20 J/cm², DCD: 30–20, 5 Tx

Photos Courtesy of Olga Zerpa, M.D.

Clinical Results – Male Ear



Pre Treatment

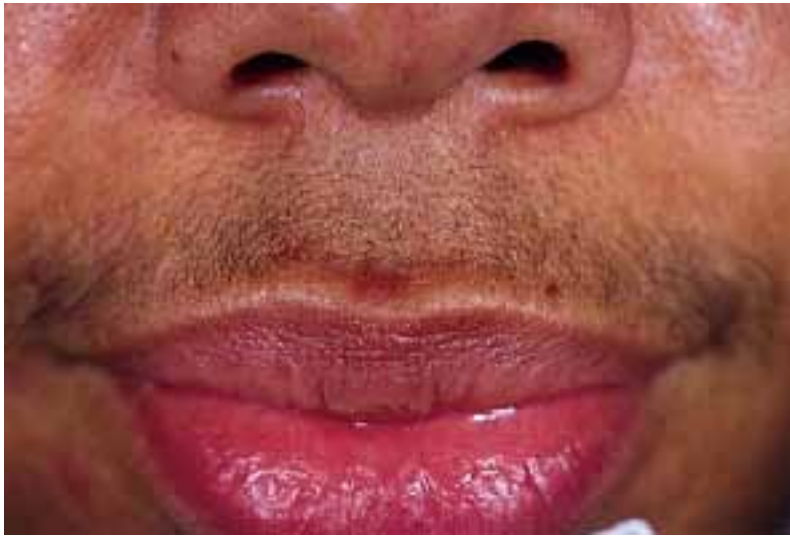

Post 3 Treatments

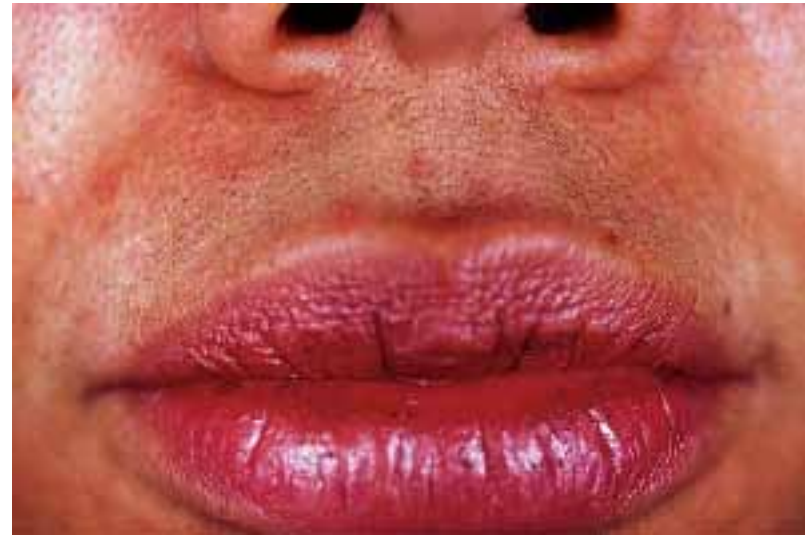10 mm, 20 J/cm², DCD: 70–10, 3 tx

Photos Courtesy of M.Elder, M.D.

Clinical Results – Female Upper Lip



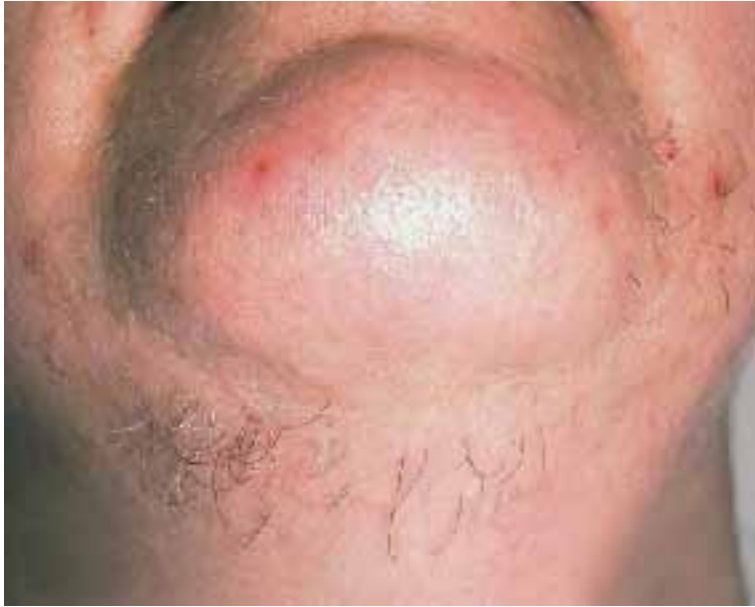Pre Treatment



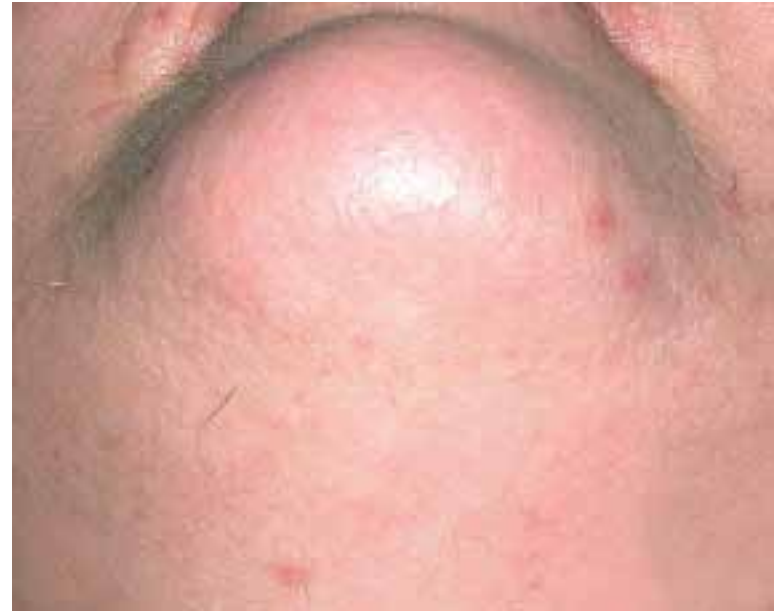Post Treatment

Photos Courtesy of E. Battle, M.D.

Clinical Results – Female Chin



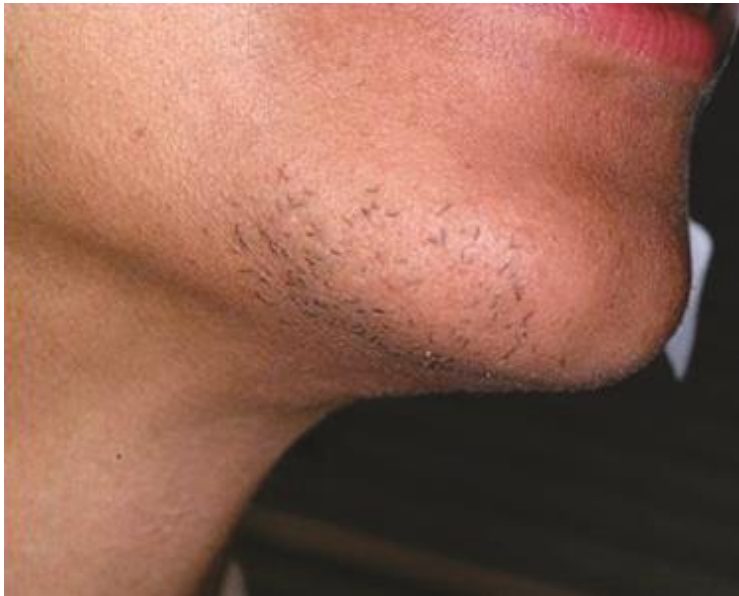Pre Treatment



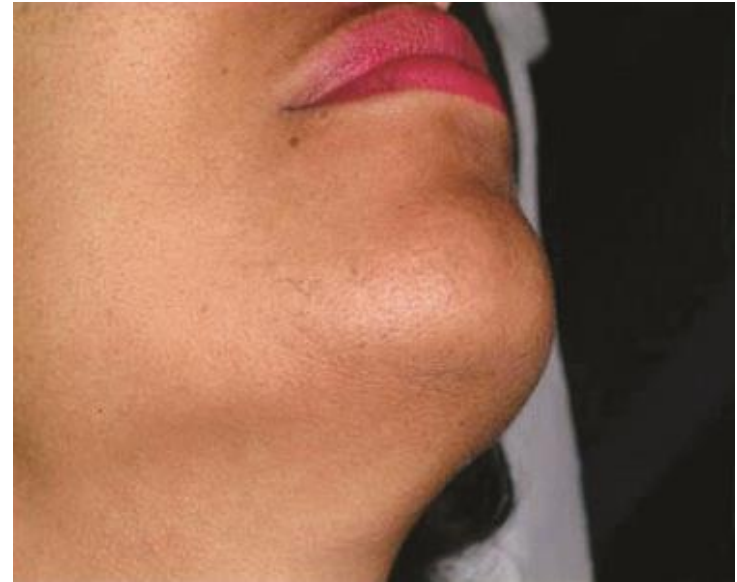Post Treatment

Photos Courtesy of S. Laughlin, M.D.

Clinical Results – Female Chin



Pre Treatment



Post 3 Treatments

12 mm, 30 J/cm², 3 ms, DCD: 40–20, 2tx

Photos Courtesy of V. Ross, M.D.